

Pulp Revascularization: Endodontical Treatment Based on Tissue Biology – Two Cases Reports

Camila Almeida de Andrade¹, Daniela Melandes da Silva¹, Karine Baldo¹, Ana Paula Simezo², Augusto Kato², Carlos Eduardo da Silveira Bueno², Caio Cesar Souza³, Patricia Costa Oliveira⁴, Fábio Silveira de Souza⁵, Yanessa Santos Muniz⁶, Danielle Maia⁶, Ana Grasiela da Silva Limoeiro⁶, Antônio Henrique Braitt⁶

¹Department of Endodontics, Instituto Baiano de Pesquisa Odontologica (Ibpo), Teixeira de Freitas, Ba, Brazil

²Department of Endodontics, Dental Research Center, São Leopoldo Mandic University, Campinas, Sp, Brazil

³Private Office

⁴Department of Radiology, School of Dentistry, Ilhéus University, Ilhéus, Ba, Brazil

⁵Department of Orthodontics, School of Dentistry, Ilhéus University, Ilhéus, Ba, Brazil

⁶Department of Endodontics, School of Dentistry, Ilhéus University, Ilhéus, Ba, Brazil

Abstract

Introduction: Pulp revascularization is a therapeutic option for the treatment of teeth with incomplete rhizogenesis and tissue necrosis that proposes the control of the infection of the root canal system in order to eliminate the symptoms and to show repair of periapical tissues, promoting thickening of the wall and continuity of apical formation, being biologically more acceptable.

Objective: The objective of this study was to report the revascularization process in 2 young patients with clinical and radiographic signs of pulp necrosis and the presence of dental fistula, following the same endodontic protocol. The canal cleaning occurred through passive ultrasonic irrigation with sodium hypochlorite, followed by medication with calcium hydroxide. After 30 days, intracanal medication was removed; bleeding was induced with subsequent clot formation and placement of a cervical MTA barrier. The coronary sealing was done with glass ionomer and composite resin. After six months, the teeth were asymptomatic and with relevant regression of the periapical lesions, according to clinical and radiographic control.

Conclusion: It was concluded that pulp revascularization, in both cases, was a viable method in the induction of root maturation with thickening of the root wall and closure of the apex, strengthening the dental structure.

Keywords: Regeneration, Calcium Hydroxide, Dental Pulp.

I. Introduction

Teeth that did not reach stage 10 of Nolla (complete root apex) are diagnosed as having incomplete rhizogenesis(1), and the treatment of these immature teeth with pulp necrosis is a challenge for professionals in endodontics(2).

The loss of pulp vitality and the interruption of root development may be caused by bacterial contamination through caries or traumatic injuries (3). Teeth with open apex have roots with thin walls and great risk of fracture, making biomechanical preparation difficult during endodontic intervention (4).

Immature teeth are treated conventionally by apexification which consists of the exchange of calcium hydroxide paste for the long term. However, this method has several disadvantages, including longer treatment time and increased risk of root fracture due to root wall thickness (3).

An apical barrier of MTA is an alternative technique to the use of calcium hydroxide, thus avoiding the periodic exchange of intracanal medication (5). However, both techniques have the same disadvantage as not allowing the continuity of root development, leaving the root fragile (2).

Revascularization is a treatment option for young permanent teeth with pulp necrosis and incomplete rhizogenesis, which allows the continuity of root development (2). This concept of endodontic treatment consists of the invagination of the connective tissue to the interior of the pulp (6), reinforcing the walls of dentin by deposition of hard tissue, strengthening them against fractures (2).

Root canal cleansing in the revascularization process occurs with the use of auxiliary chemicals and the use of antibiotic paste (6,7) or calcium hydroxide (6,8), since the mechanical removal of microorganisms in immature teeth is limited due to the thin wall radicular thickness (8). Induction of bleeding is performed with a

sterile instrument passing through the apical foramen. The formation of the blood clot within the canal serves as a guide for tissue invagination (9). Then, the MTA plug must be performed, and in order to avoid coronary infiltration, the tooth must be sealed with glass ionomer and composite resin (2,4,9,10).

This study aimed to present two clinical cases of revascularization in young permanent teeth with incomplete rhizogenesis, pulp necrosis and fistula.

II. Case report

Patient J.V.A.R., male, 14 years old, was indicated by the orthodontist to perform endodontic treatment of the tooth 11, asymptomatic, due to the presence of a fistula in the underlying gingival insert. During the anamnesis, the patient reported a trauma to this tooth at the age of seven when he suffered a cycling accident. The patient's mother signed the informed consent form, authorizing treatment. Clinical examination revealed a fistula in the inserted gingiva and incisal fracture of unit 11 (Figure 1).

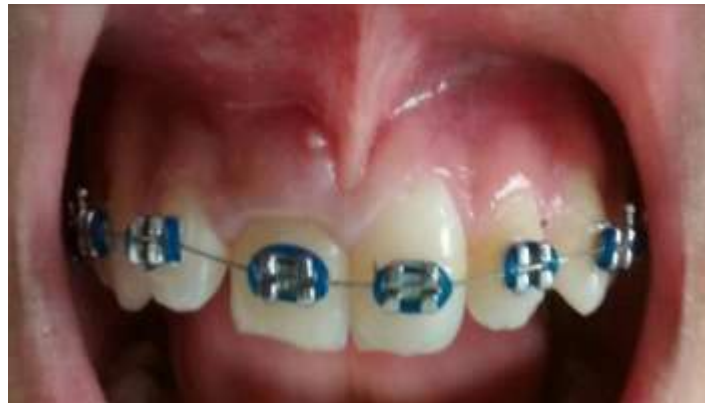

Figure 1: Tooth 11 with incisal fracture and dental fistula.

The tooth had a negative response to the palpation, vertical and horizontal percussion tests and the sensitivity test. Radiographic examination revealed that the root canal presented incomplete rhizogenesis (Figure 2). The orthodontic wire was removed and the fistula was screened using a gutta-percha cone (Figure 3).

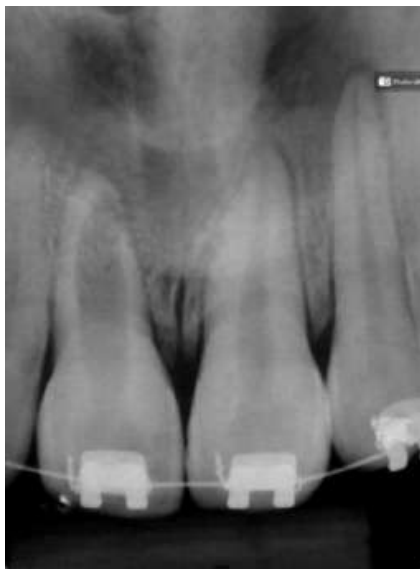

Figure 2: Initial radiograph.

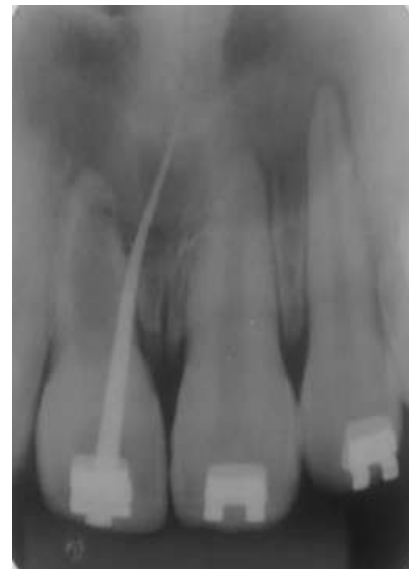

Figure 3: Fistula screening

The tooth was anesthetized with 4% articaine with epinephrine 1: 100,000, absolute isolation was performed using clamp 206. The canal was irrigated with 20 mL of 2.5% NaOCl, draining purulent and bloody secretion. After 7 days, the fistula disappeared (Figure 4).

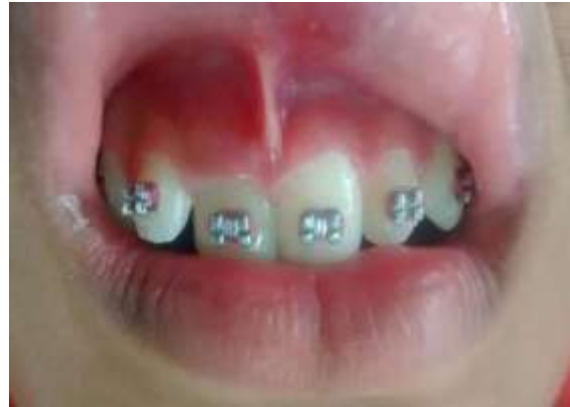

Figure 4: Absence of fistula after 1 week

Irrigation was performed with 10ml NaOCl at 2.5% to remove necrotic remains from the interior of the canal. Ultrasonic passive activation (PUI) was performed with an ultrasonic tip E1- Irrisonic (Helse, SP, Brazil), in 3 cycles of 20 seconds, 2.5% NaOCl, 17% EDTA and 2.5% NaOCl (11).

The canal was dried with absorbent paper tips, decreasing 2 mm of the length of the tooth in the radiography, trying to minimize injuries to the cells of the periapical region. The intracanal medication was performed with calcium hydroxide and the temporary restoration was done with glass ionomer.

After 30 days, a new intervention was performed and calcium hydroxide was removed with 17% EDTA activated with ultrasonic tip(Irrisonic, Helse), followed by final irrigation with 10 ml of sodium hypochlorite a 2.5% and 5 ml of saline solution. Induction of apical bleeding was performed with a manual sterile instrument # 40 (Dentsply / mailefer)(2,3,4,9,10). Then, 15 minutes were waited for clot formation. The MTA was placed at the entrance of the canal and then a double sealing was performed with glass ionomer and composite resin.

After six months, there were no clinical signs and symptoms, such as pain on palpation or percussion. On radiographic examination, a significant regression of the periapical lesion, increase of radicular wall thickness and onset of radicular apex formation was observed (Figure 5). At the sensitivity test with Spray refrigerant, the patient did not feel pain, but reported feeling the presence of the cold stimulus.

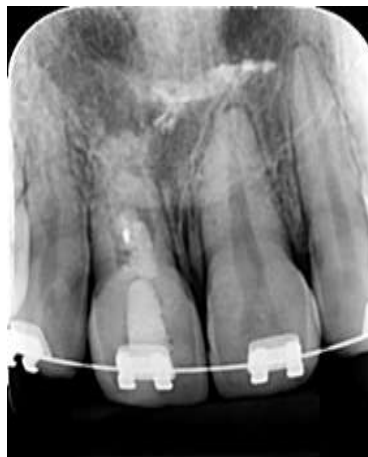

Figure 5: Control after 7 months

III. Case Report

The patient, Y.R.F, 13 years old, attended the CEO (Center of Dental Specialties) of the city of Eunápolis - Ba, accompanied by her grandmother, who signed a free and informed consent form authorizing the treatment.

Clinical examination revealed a slight alteration in tooth color 33 and presence of a fistula in the marginal gingiva, but with no symptoms (Figure 6).

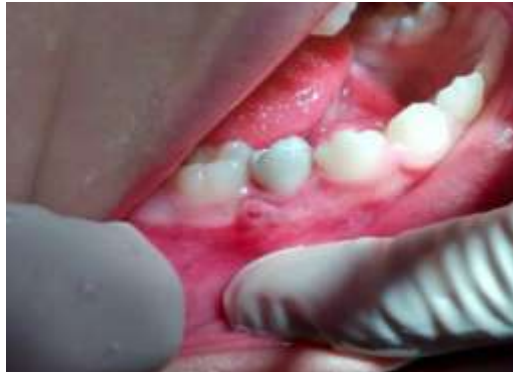

Figure 6: Clinical aspect - presence of fistula

In the initial radiography, occlusal decay was observed, apex with incomplete formation and periapical lesion on tooth 33 (Figure 7).

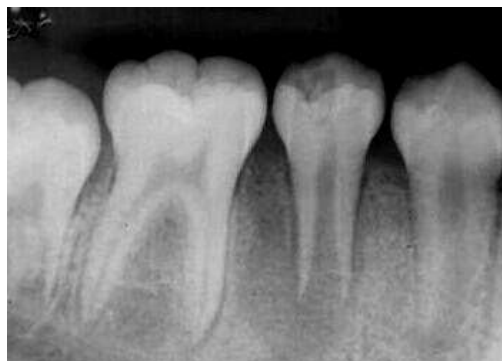

Figure 7: Radiographic appearance - incomplete rhizogenesis

Due to evidence of necrosis, the pulp sensitivity test with coolant spray and anesthesia were not performed prior to the procedure. However, during the access surgery, there was intense red-spot bleeding and a granulation tissue was present. At the moment of the initial exploration of the canal, with type K 30 file, the patient reported pain sensation. Anesthesia with lidocaine 2% epinephrine 1: 100,000 were then performed. Initial irrigation was performed with 20 ml of 1% sodium hypochlorite.

Due to the persistence of bleeding, it was decided to insert sterile cotton at the entrance of the canal and temporary restoration.

After 8 days, the dressing was removed with 10 ml irrigation and 1% sodium hypochlorite and ultrasonic passive activation (PUI) using the E1 - Irrisonic ultrasonic tip in 3 cycles of 20 seconds (11).

Afterwards, the canal was dried with an absorbent paper tip and the intracanal medication was placed.

After 30 days, the calcium hydroxide was removed with 17% EDTA activated with E1-Irrisonic. Thereafter, 10 ml of sodium hypochlorite and 5 ml of saline were added. Induction of bleeding was performed using a sterile K # 40 file, exceeding the apical radiographic limit by 2 mm. Sterile cotton was required for approximately 10 minutes until clot formation.

Soon after, a cervical barrier of MTA and double sealing with glass ionomer and the composite resin was made. After removal of the rubber dam, a final radiograph was made (Figure 8).

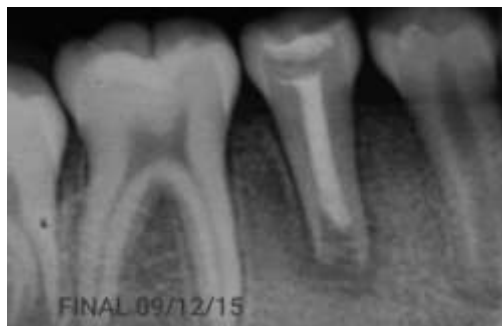

Figure 8: Final radiography

After 7 months, the patient still had no clinical symptoms and no fistula. In the radiographic evaluation, it was observed absence of periapical lesion and a considerable apical formation, suggesting that the treatment obtained positive results. A vitality test was performed and the patient did not report pain to the test, but remained without signs and symptoms, until the present date (Figure 9).

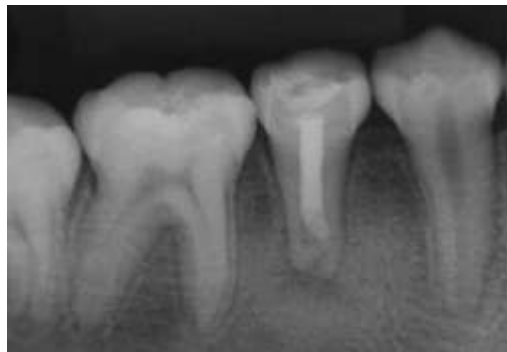


Figure 9: X-ray of preservation after 7 months of treatment

IV. Discussion

At the present time of endodontic, one of the most interesting topics is the regeneration of pulp tissue (12). The literature shows that, in this type of procedure, the results are acceptable in specific situations of young teeth, such as apices with at least 1mm opening and remaining viable pulp. In addition, the presence of living tissue inside the root prevents bacteria from contaminating the space (6).

In the two cases reported, it was decided to use the advantages of the technique of revascularization instead of the traditional apexification with the aim to obtain its benefits that include the continuation of the apical development and reinforcement of the radicular structure (13). One of the disadvantages of the apexification is the presence of thin root walls, leaving the tooth susceptible to fracture after endodontic treatment. (14).

At the first moment, the protocol that must be followed involves an abundant root canal sanitation with auxiliary chemical substances for the therapy to be effective, and it is essential that the bacterial control is successfully achieved (15), since the mechanical removal of the microorganisms in immature teeth is due to the thin thickness of the root walls.

Sodium hypochlorite in concentrations ranging from 2.5 to 6% has been well used as an auxiliary chemical in cases of pulpal revascularization (6), or chlorhexidine in concentrations of 2% (8) and 0.12% (15) and satisfactory clinical results have been obtained. In case 1, we opted for abundant irrigation with 2.5% sodium hypochlorite, besides the passive ultrasonic activation of this substance. However, in Case 2, 1% sodium hypochlorite was used because it was the only one available in the care unit.

The most commonly used technique to complement pulpal revascularization during its decontamination involves the use of an antibiotic triple paste consisting of metronidazole, ciprofloxacin and minocycline, which has been shown to be effective against pathogens commonly found within the root canal system (2,3, 4,8,9,10). A disadvantage linked to the triple antibiotic paste concerns discoloration of the crown caused by the presence of minocycline, which could be demonstrated in several studies (14,16,17,18,19).

Concerning these considerations on the use of the triple antibiotic paste, calcium hydroxide was the drug of choice, representing another successful alternative when used as intracanal medication in the root canal system during pulpal revascularization (13,20). The high pH of calcium hydroxide can neutralize the acidity produced by the present tissue destruction, creating a favorable environment for repair (21,22). On the other hand, some authors have reported that it is not recommended to use calcium hydroxide as intracanal medication in cases of pulpal revascularization of immature teeth, believing that the use of this medication prevents the preservation of remaining pulp tissue inside the root canal, which would serve as matrix for the development of a new tissue, besides the cells of the Hertwig sheath, responsible for the root rhizogenesis, would be jointly harmed by the use of calcium hydroxide (9,22). In contrast, the results of some studies investigating the influence of some drugs used as intracanal medication, including triple antibiotic paste and calcium hydroxide, on the survival capacity of undifferentiated mesenchymal cells present in the apical papilla and involved in regenerative endodontic processes have proven that most of the drug combinations used directly impair the viability of these cells and may interfere with the regenerative process. All the drugs studied were able to cause toxicity to the undifferentiated mesenchymal cells in the apical papilla, proportionally to the applied concentration, except calcium hydroxide that promoted the survival of these cells independent of its concentration (22). In view of this, we can infer that the choice of calcium hydroxide as medication, in these

cases, provided adequate decontamination of the root canal and avoided aesthetic discoloration from minocycline.

According to Dali and Rajbanshi (12), pulpal regeneration technique requires normal and sterile granulation tissue within the root canal from a blood clot, simulating odontoblastic or mesenchymal cells capable of forming calcified tissue at the apex and the lateral wall. Several authors agree that this bleeding should be provoked at the apex through a sterile K-type file or even with a manual instrument that is also sterile (2,3,4,9,10). In the canal space, the tissue formed is not pulp and does not function as pulp tissue, which means that revascularization is not the regeneration of the pulp, but resembles the process of wound repair (2).

The preparation of the MTA plug should be done on the clot to prevent bacteria from entering the root canal before pulp revascularization, developing a coronary seal against bacteria, and preventing any recontamination of the root canal (2,3,4).

The literature shows that the first six months after the completion of treatment are crucial in successful treatment. Throughout this period it is possible to assess whether there was indeed root development (24,25). Clinical case 1, after six months of preservation, was asymptomatic, with disappearance of the fistula and radiographic signs of repair, such as a decrease in the periapical lesion and the apical foramen amplitude. In clinical case 2, in addition to the evidence already mentioned in clinical case 1, it was also possible to verify the closure of the root apex.

The clinical and radiographic preservation of young permanent teeth submitted to this process should be from 6 to 26 months (2,3,4,9,10,13).

V. Conclusion

Pulpal revascularization was a viable method in the induction of root maturation with thickening of the root wall and closure of the apex, strengthening the dental structure due to absence of symptomatology, disappearance of the fistula, absence of clinical symptoms and presence of radiographic signs of repair.

Acknowledgements

References

- [1]. LEONARDO M, Leal JM. **Tratamento De Canais Radiculares**. 3ª Ed. São Paulo: Panamericana; 1998.
- [2]. NOSRAT A, SEIFI A, ASGARY S. **Regenerative Endodontic Treatment Revascularization For Necrotic Immature Permanent Molars: A Review And Report Of Two Cases With A New Biomaterial**. J Endod. 2011; 37(4):562-7.
- [3]. DING RY, CHEUNG GS, CHEN J, YIN XZ, WANG Q, ZHANG C. **Pulp Revascularization Of Immature Teeth With Apical Periodontitis: A Clinical Study**. J Endod. 2009; 35(5):745-9.
- [4]. COTTI E, MEREU M, LUSSO D. **Regenerative Treatment Of A An Immature Traumatized Tooth With Apical Periodontitis: Report Of A Case**. J Endod. 2008;34(5)611-6.
- [5]. SHABAHANG S, TORABINEJAD M, BOYNE PP, ABEDI H, Mcmillan P. **A Comparative Study Of Root-End Induction Using Osteogenic Protein-1, Calcium Hydroxide, And Mineral Trioxide Aggregate In Dogs**. J Endod. 1996;29(2):118-24.
- [6]. IWAYA S, IKAWA M, KUBOTA M. **Revascularization Of An Immature Permanent Tooth With Apical Periodontitis And Sinus Tract**. Dent Traumatol 2001;17:185–187.
- [7]. LOVELACE TW, HENRY MA, HARGREAVES KM, DIOGENES A. **Evaluation Of The Delivery Of Mesenchymal Stem Cells Into The Root Canal Space Of Necrotic Immature Teeth After Clinical Regenerative Endodontic Procedure**. J Endod. 2011;37(2):133-8.
- [8]. SHIN SY, ALBERT JS, MORTMAN RE. **One Step Pulp Revascularization Treatment Of An Immature Permanent Tooth With Chronic Apical Abscess: A Case Report**. I Endod J. 2009;42(12):1118-26.
- [9]. BANCHS F, TROPE M. **Revascularization Of Immature Permanent Teeth With Apical Periodontitis: New Treatment Protocol?** J Endod. 2004;30(4):196-200.
- [10]. THIBODEAU B, TROPE M. **Pulp Revascularization Of A Necrotic Infected Immature Permanent Tooth: Case Report And Review Of The Literature**. Pediatr Dent. 2007;29(1): 47-50.
- [11]. VAN DER SLUIS LWM, VOGELS MPJM, VERHAAGEN B, MACEDO R, WESSELINK APR. **Study On The Influence Of Refreshment/Activation Cycles And Irrigants On Mechanical Cleaning Efficiency During Ultrasonic Activation Of The Irrigant**. J Endod 2010;36:737-40.
- [12]. DALI M, RAJBANSHI L. **Regenerative Endodontics: Changes, Chances Of Challenges Revascularization In Pediatric Dentistry**. Journal Of Research In Dental Sciences. 2014;5:186-9.
- [13]. BOSE R, NUMMIKOSKI P, HARGREAVES K. **Retrospective Evaluation Of Radiographic Outcomes In Immature Teeth With Necrotic Root Canal Systems Treated With Regenerative Endodontic Procedures**. J Endod. 2009;5(10):1343-49.
- [14]. CHEN MY, CHEN KY, CHEN CA, TAYEBATY F, ROSENBERG PA. **Responses Of Immature Permanent Teeth With Infected Necrotic Pulp Tissue And Apical Periondontitis To Revascularization Producers**. J Endod. 2008;30(3):6-12.
- [15]. PETRINO JA, BODA KK, SHAMBARGER S, BOWLES WR, Mcclanahan SB. **Challenges In Regenerative Endodontics: A Case Series**. J Endod.2010;36(3):536-41.
- [16]. DODD MA, DOLE EJ, TROUTMAN WG, BENNAHUM DA. **Minocycline – Associated Tooth Staining**. Ann Pharmacother. 1998;32(9):887-9.
- [17]. MCKENNA BE, LAMEY PJ, KENNEDY JG, BATESON J. **Minocycline-Induced Staining Of The Adult Permanent Dentition: A Review Of The Literature And Report Of A Case**. Dental Update. 1999;26(4):160-2.
- [18]. TREDWIN CJ, SCULLY C, BAGGAN-SEBASTIAN J V. **Drug-Induced Disorders Of Teeth**. J. Dent. Res. 2005;84(7):596-602.
- [19]. KIM JH, KIM Y, SHIN SJ, PARK JW, JUNG Y. **Tooth Discoloration Of Immature Permanent Incisor Associated With Triple Antibiotic Therapy: A Case Report**. J Endod. 2010;36:1086-91.

- [20]. CHEN MY, CHEN KY, CHEN CA, TAYEBATY F, ROSENBERG PA. **Responses Of Immature Permanent Teeth With Infected Necrotic Pulp Tissue And Apical Periondontitis/Abscess To Revascularization Producers.** I Endod J. 2012;45(3):294-305.
- [21]. VAES G. **Lysosome And Cellular Physiology Of Bone Resorption.** In: **Lysosomes In Biology And Phatology.** Amsterdam N Holl Publis. 1969:216-53.
- [22]. CHUEH LH, HUANG GTT. **Immature Teeth With Periradicular Peridontitis Or Obscess Undergoing Apexogenesis: A Paradigm Shift.** J. Endod.2006;32(12):1205-13.
- [23]. RUPAREL NB, TEXEIRA FB, FERRAZ CCR, DIOGENES A. **Direct Effect Of Intracanal Medicaments On Survival Of Stem Cells Off The Apical Papilla.** J. Endod. 2012;38(10):1372-75.
- [24]. ALBUQUERQUE MTP, NAGATA JY, SOARES AJ, ZAIA AA. **Pulp Revascularization: An Alternative Treatment To The Apexification Of Immature Teeth.** RGO. 2014;62:401-410.
- [25]. LIMOEIRO AGS, BRAITT AH, KATO AS, FREIRE LG, BUENO CES. **Pulp Revascularization: A Case Report.** Dental Press Endod. 2015 May-Aug;5(2):74-7.